

Management of Periodontal-Endodontic Lesion by Regenerative Approach: A Case Report

Anika Daing¹, Vimal Arora²

¹ (MDS, Assitant Professor, Department Of Periodontology, Faculty Of Dentistry, Jamia Millia Islamia, New Delhi

² (BDS, Private Practitioner, New Delhi)

Abstract: Endodontic-periodontal lesion has been a diagnostic challenge. The present case report describes a case of localized primary periodontal lesion with secondary endodontic involvement in maxillary premolar. Its management was done by root canal therapy followed by periodontal regenerative procedure using Guided tissue regeneration technique.

Keywords: endodontic-periodontal lesion, guided tissue regeneration, root canal therapy

I. Introduction

Relationship between periodontium and endodontium was first described by Simring and Goldberg [1] in 1964. The periodontal-endodontic lesion leads to involvement of tooth pulp and periodontal diseases in the same tooth which makes it difficult to diagnose and treat. The pathways for spread of bacteria between pulpal and periodontal tissues is discussed in the literature with controversies. The most conventional and followed classification, is given by Simon et al [2] into following groups: 1. Primary endodontic lesion 2. Primary endodontic lesion with secondary periodontal involvement, 3. Primary periodontal lesion, 4. Primary periodontal lesion with secondary endodontic involvement 5. True combined lesions.

Treatment of periodontal-endodontic lesions require both endodontic therapy and periodontal regenerative procedures. This article presents a case report of a primary periodontal lesion with secondary endodontic involvement in upper premolar. This was first treated by conventional endodontic treatment followed by periodontal regenerative procedure using Guided tissue regeneration and bone graft.

II. Case report

A female patient aged 40 years complained of pain and pus discharge from right maxillary first premolar since 3 months. She was systemically healthy and medical history was non-contributory. On clinical examination, there was a generalized excessive plaque and calculus. Tooth no 14 was Grade II mobile with draining pus through gingival sulcus [Fig. 1]. Probing pocket depth of 10 mm, 10mm, 8mm and 4mm was recorded respectively on mesial, buccal, distal and palatal aspects of the maxillary first premolar. Tooth was non carious, however was non-vital as it didn't respond to thermal or electric pulp tester. Intra-operative periapical radiograph (IOPAR) showed a deep bony defect on mesial aspect of tooth 14 extending till root apex [Fig.2]. Based on clinical, and radiographic examination, a diagnosis of periodontal lesion with secondary endodontic involvement was made for tooth 14.

On first appointment emergency treatment was done, which included abscess drainage with administration of antibiotic regimen and analgesics for 5 days. On next appointment, full mouth scaling root planing was done followed by occlusal reduction and root canal procedure for tooth 14. Re-evaluation of patient after 1 week showed decrease in swelling and inflammation. This was followed by periodontal flap surgery for tooth 14.

2% local anaesthesia with 1:200000 adrenaline as administered and vertical incision was given at mesial line angle of 13 and sulcular incisions from 13 to 16. A full thickness mucoperiosteal flap was raised. Circumferential bone defect extending till apex with root dehiscence was observed in relation to tooth 14 [Fig.3]. Granulation tissue was removed and thorough root planing was done with Hu-Friedy Gracey curettes. Hydroxyapatite crystals (Sybografit) were placed in the bone defect [Fig.4] and root dehiscence was covered by resorbable collagen membrane (Periocol). Flap was sutured with 3-0 silk suture and Coe-Pack was placed [Fig.5]. Post operative instruction with medication were given.

After 1 week Coe pack and sutures were removed and soft tissue healing was satisfactory. At 3 months, it was observed that mobility of tooth was reduced from Grade II to Grade I. At 6 months, IOPAR showed good bone formation [Fig.6]. Probing pocket depth was reduced to 6mm, 6mm, 3mm and 5mm respectively on distal, buccal, mesial and palatal side.

III. Discussion

Inflammatory inter-communication between pulpal and periodontal lesions leads to endodontic-periodontal lesion. They are difficult to diagnose and treat because a single lesion may presents sign of both endodontic and periodontal involvement. Proper history taking and sequential treatment planning are imperative for success of these lesions.

In the present case, there was no carious lesion in tooth no 14; however tooth was associated with deep periodontal pockets and tooth was also non vital. Radiographic examination showed advanced periodontal bone loss in relation to 14. These findings were suggestive of diagnosis of periodontal lesion with secondary endodontic involvement according to Simons Classification. Three main pathways have been implicated in the development of periodontal-endodontic lesions: apical foramen, lateral and accessory canals and dentinal tubules^[3,4]. Main cause of the periodontal lesions is the presence of bacterial plaque formed by aerobic and anaerobic microorganisms. Various theories have been suggested in the literature regarding spread of infection from periodontium to pulp. Lindhe et al^[5] reported that bacterial components of the inflammatory process may reach the pulp when there is accessory canal exposure or through apical foramen. Rubach and Mitchell^[6] also suggested the possible role of accessory canals in the pathways of periodontal lesion with secondary endodontic involvement. However, Adriaens et al^[7] demonstrated that dentinal tubules act as a main reservoir for microorganisms. In the present case also a possible source of necrosis of pulp in absence of carious lesion could be ingress of periopathogens from periodontal pocket into pulp via lateral or accessory canals.

Treatment of combined endodontic periodontal lesion requires a root canal treatment for healing endodontic component followed by periodontal regeneration. In this case also similar treatment plan was followed. Guided tissue regeneration(GTR) therapeutic protocol involves surgical placement of cell occlusive membrane facing the bone surface to physiologically seal off the site and create secluded space. It provides with an environment for the osteoprogenitor cells and expression of the osteogenic activity. Non resorbable barrier membrane were used since the start of the concept. However due to need for second surgical intervention and increased chance of exposure; there has been a preference for biodegradable membrane for GBR procedure. In the present case we have used bioresorbable fish collagen membrane. These membranes have several desirable properties like cell adhesion, chemotactic and adhesive properties for a regenerative procedure. Additionally, bone grafts have been utilized as a membrane supporting device in ridge augmentation procedure with encouraging clinical results.^[8] Previously mentioned reports in the literature have found clinical advantage of using Hydroxyapatite bone graft in combination with collagen membrane^[9,10]. Hydroxyapatite shows osteoconductive properties and act as a scaffold for the in-growth and subsequent deposition of the new bone. Similar to our case, Verma et al^[4] and Agarwal et al^[11] also illustrated successful treatment of endo- perio lesion by root canal treatment, following which periodontal surgery using collagen membrane and bone grafting was done.

IV. Conclusion

Endodontic periodontal lesions presents a diagnostic and treatment challenge .It can be successfully managed by root canal therapy followed by periodontal therapy. Guided tissue regeneration techniques using alloplastic membrane and resorbable collagen membrane can be effectively used in its treatment.

References

- [1]. SimringM, Goldberg M. The pulpal pocket approach: Retrograde periodontitis. J Periodontol 1964; 35:22-48
- [2]. Simon JH, Glick DH, Frank AL. The relationship of endodontic-periodontal lesions. J Clin Periodontol 1972;43:202
- [3]. RajaSV, EmmadiP, NamasivayamA, ThyegrajanR, RajaramanV. The periodontal-endodontic continuum: A review. J Consev Dent 2008 Aprl-Jun;11(2):54-62
- [4]. Verma PK, Srivastava R, Gupta KK, Srivastava A. Combined endodontic-periodontal lesion :A clinical dilemma J Interdiscip Dentistry 2011;1:119-24
- [5]. Lindhe J, Tratado De Periodontia Clínicae Implantologia Oral, Guanabara Koogan, Rio de Janeiro, Brazil, 3rd edition, 1999.
- [6]. Rubach WC and Mitchell DF "Periodontal disease, accessory canals and pulp pathosis," J Pertodontol 1965;36:34-38 .
- [7]. Adriaens PA , Edwards CA, de Boever JA, and Loesche WJ.Ultrastructural observations on bacterial invasion in cementum and radicular dentin of periodontally diseased human teeth J Periodontol 1988;59:493-503
- [8]. Singh A, Daing A, Dixit J, Anand V. Two dimensional alveolar ridge augmentation using particulate hydroxyapatite and collagen membrane: A case report J Oral Biol Craniofac Res 2014 May-Aug; 4(2): 151-154.
- [9]. Daing A, Singh, A, Dixit J, Anand V. Management of periodontal lesion associated with traumatic deep bite: a case report. International J dent case reports 2012;2 (3):48-53
- [10]. Daing A, Sybil D, Bhardwaj A, Singh S. Guided tissue regeneration for treatment of lateral periodontal cyst: Report of a case International J Contemp Dentistry 2016: 6
- [11]. Agarwal R, Singh V, Kambalyal P, Jain K. Management of endo -perio lesion with regenerative approach-A case report. Int J Oral Health Med Res 2016;3 (1):119-121

Figures with legends

Fig 1 Generalized excessive plaque and calculus with draining pus through gingival sulcus of tooth no 14.

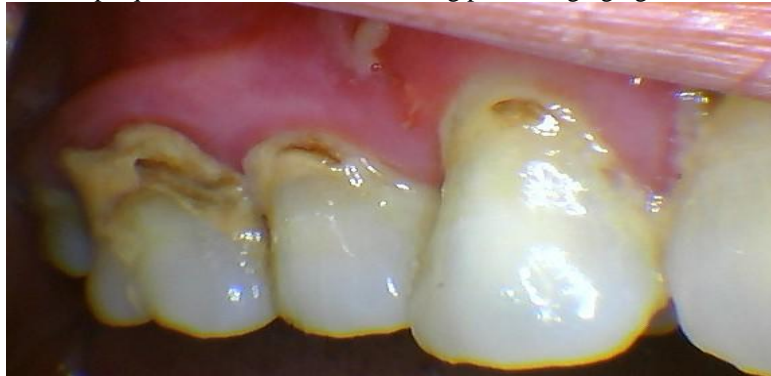

Fig.2: IOPAR showed a deep bony defect on mesial aspect of tooth 14 extending till root apex.

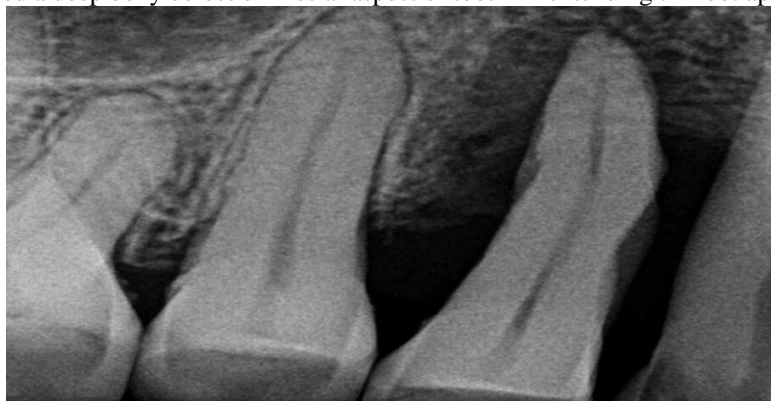


Fig 3: A full thickness mucoperiosteal flap was raised and circumferential bone defect extending till apex with root dehiscence was observed in relation to tooth 14.

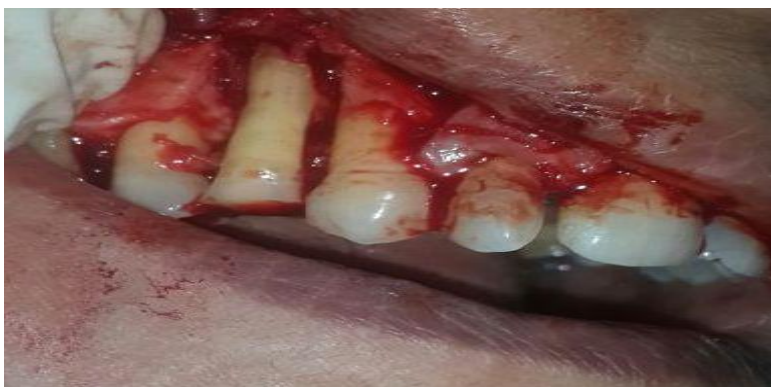

Fig 4: Hydroxyapatite crystals were placed in the bone defect.

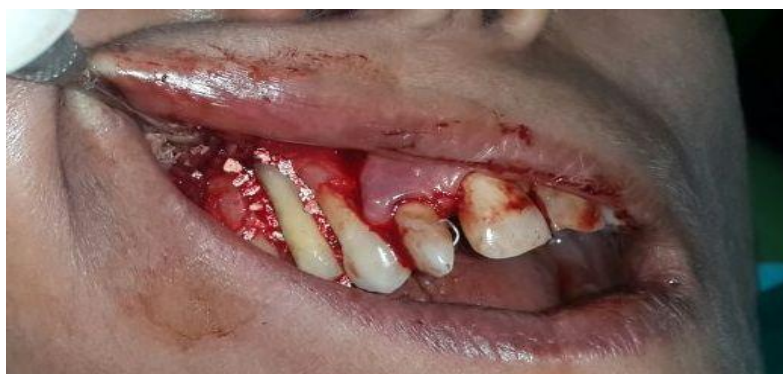

Fig.5: Flap was sutured with 3-0 silk suture.

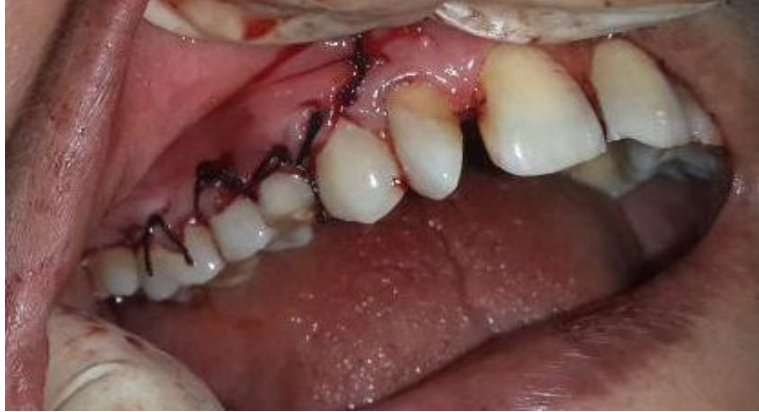

Fig6: IOPAR at 6 months showing bone fill in the defect

